

# MAXIM 3D<sup>TM</sup>

## FREEDOM IN DESIGN

### CASE REPORT



**MAXIM 3D**

**ACCUVAULT OVER DRAIN TUBE**

### GLAUCOMA SHUNTS AND KERATOCONUS

**WRITTEN BY  
MICHAEL DINAPOLI  
DINAPOLI OPTICIANS**

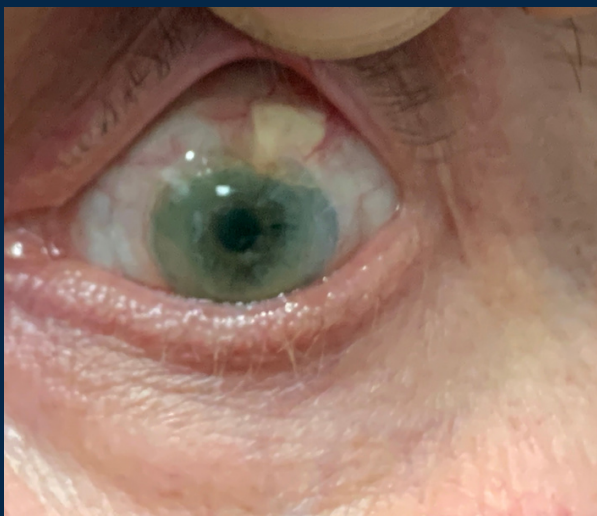M.K. is a 67 year-old male with a history of irregular corneas, uncontrollable glaucoma pressures and very poor vision as a result of unsuccessful cataract surgery ou. He is also amblyopic O.S. with minimally correctable vision of R 20/80 L 20/200.

I've been fitting M. K. on and off for two years. He was presented with binocular glaucoma with associated "drain tubes" and a trabeculectomy on his superior left scleral. He also had keratoconus ou and he was told that he should not wear rigid contact lenses, specifically scleral contact lenses.

I fitted M.K. with a small RGP lenses to a fairly successful OD 20/50 and OS 20/100+

M.K. switched glaucoma specialists in late 2020 due to his frustration of hard-to-control pressures and his inability to see clearly. He wanted to get back to work as an engineer and start to drive again.

His new glaucoma doctor allowed him to get ANY contact lens that might improve his vision. During that time, we had received and set up our Eaglet Profile Analyzer.



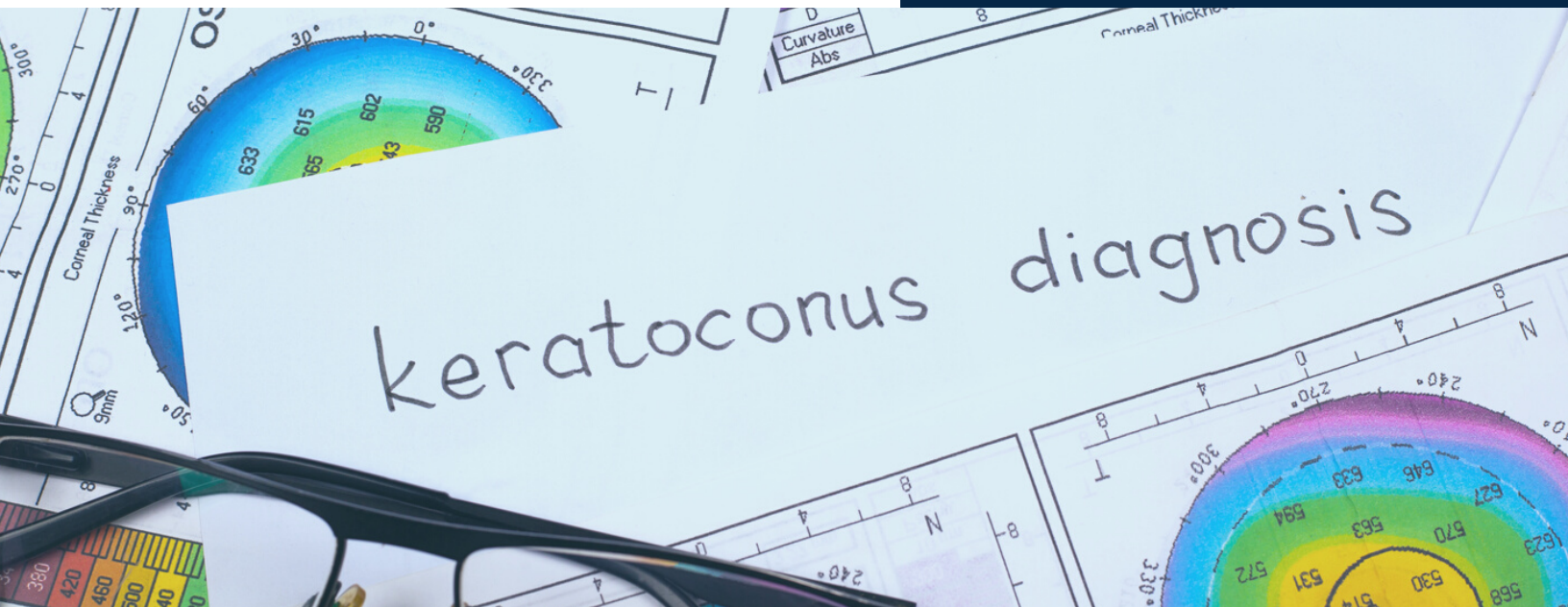
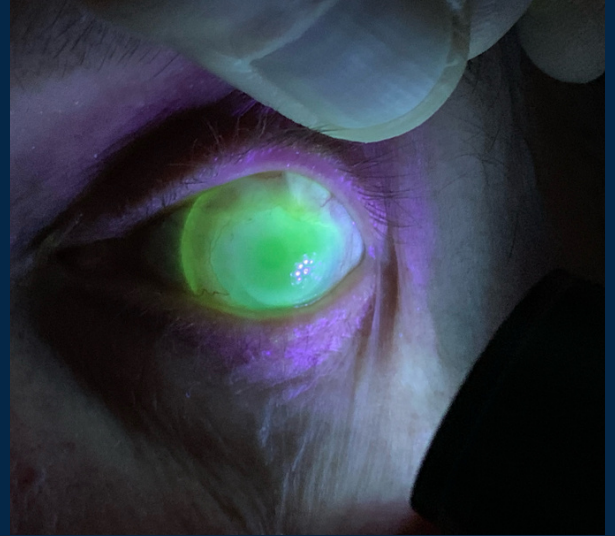## A CHALLENGING CASE

On April 1, 2021, M.K. was one of our first patients on the Eaglet. We were all excited about trying to fit M.K. with quadrant-specific MAXIM SCLERAL LENSES, based on the readings that we obtained from the Eaglet maps. We exported the data and Acculens designed our first scleral lens based on the findings from the Eaglet Analyzer. The lens was dispensed about (3) weeks later by myself and Steve Cogger, our consultant from Acculens. We placed the lens on the left eye and WOW, a 95% perfect fit, though we miscalculated the Rx. The lens was re-ordered in the proper Rx and dispensed (2) weeks later. M.K. was immediately very comfortable and achieved about 20/80 vision, the best that he had seen in decades!

The lens had minimum, but ample clearance, over his trabeculectomy elevation. It was dispensed and checked (2) weeks later, WITH NO INSULT TO THE SCLERA where the elevated tissue was.

M.K. was extremely happy and is looking forward to having the right eye re-fit to a scleral lens after his glaucoma specialist is comfortable with the results of the left eye in a few months.

Kudos to Troy and Crystal, and the lab at Acculens for mastering this new technology!



*A dedicated thirty-nine year account of  
Acculens,  
Mike DiNapoli and staff at DiNapoli  
Opticians*

**Contamac<sup>™</sup>**

800-525-2470  
info@acculens.com

